Bronchoalveolar Lavage in Sarcoidosis

Marjolein Drent, M.D., Ph.D.,[1] Khaled Mansour, M.D.,[1] and Catharina Linssen, M.D.[2]

ABSTRACT

There is no single cell type present in bronchoalveolar lavage (BAL) fluid that appears to be predictive for sarcoidosis. However, BAL fluid analysis can be very helpful in the differential diagnosis. A grouping of features, an elevated total cell count, predominantly lymphocytes, together with a nearly normal percentage of eosinophils and polymorphonuclear neutrophils and the absence of plasma cells, distinguish the most likely diagnosis of sarcoidosis from the most common interstitial lung diseases, extrinsic allergic alveolitis (EAA), nonspecific interstitial pneumonia (NSIP), and idiopathic pulmonary fibrosis (IPF). In sarcoidosis the majority of cases have an increased number of lymphocytes and a normal amount of eosinophils and neutrophils. Disease presentation or activity at the time the BAL is performed as well as the smoking status is crucial for interpretation of individual BAL fluid analysis results. In severe cases the number of neutrophils can be increased as well. For an individual case the CD4:CD8 ratio is of less importance because it can be increased, normal, and even decreased. In the follow-up depicting prognosis and response to treatment, BAL fluid analysis has less clinical relevance.

KEYWORDS: BAL, differential diagnosis, sarcoidosis

Because sarcoidosis is a multiorgan disorder, patients may initially present to various organ specialists, depending on the symptoms.[1] In evaluating a patient with suspected sarcoidosis, medical history, chest radiography, and high-resolution computed tomographic (CT) scan are useful. The basic information obtained from such an evaluation guides the clinician to order the appropriate tests and make the correct diagnosis. The diagnostic approach to sarcoidosis is a complex procedure. There is no single diagnostic test for sarcoidosis. The presence of noncaseating granulomas in a single organ such as skin does not establish a diagnosis of sarcoidosis. The finding of a granuloma is not specific for this disease because many other conditions can cause granulomas. The diagnosis is based on three criteria: a compatible clinical or radiological picture, histological evidence of noncaseating granulomas, and exclusion of other diseases that may produce a similar histological or clinical picture.[1–3]

The clinical picture depends on the type of onset. Acute sarcoidosis has an abrupt onset and may present as Löfgren syndrome[1–3] (erythema nodosum with bilateral hilar adenopathy and ankle arthritis). Chronic sarcoidosis has an insidious onset, and organ-related symptoms are often caused by the pulmonary infiltration. It is important to know that nonspecific constitutional symptoms, including fever, weight loss, and fatigue, may occur in a high proportion of patients. The chest radiographic findings have various diagnostic reliability: stage I disease has an accuracy of 98% and thus a high diagnostic reliability, which is still high in stage II (89%) but is low in the other stages. Biopsies

[1]Department of Respiratory Medicine, [2]Department of Medical Microbiology, Sarcoidosis Management Centre, University Hospital Maastricht, Maastricht, The Netherlands.

Address for correspondence and reprint requests: Marjolein Drent, M.D., Ph.D., Sarcoidosis Management Centre, Department of Respiratory Medicine, University Hospital Maastricht, P.O. Box 5800, 6202 AZ Maastricht, The Netherlands (e-mail: m.drent@ lung.azm.nl).

Bronchoalveolar Lavage; Guest Editors, Robert P. Baughman, M.D., Ulrich Costabel, M.D., and Keith C. Meyer, M.D.

Semin Respir Crit Care Med 2007;28:486–495. Copyright © 2007 by Thieme Medical Publishers, Inc., 333 Seventh Avenue, New York, NY 10001, USA. Tel: +1(212) 584-4662.
DOI 10.1055/s-2007-991521. ISSN 1069-3424.

Downloaded by: RWTH Aachen. Copyrighted material.

can be obtained from easily accessible organs, such as peripheral lymph nodes, or the skin.[1] In most cases, fiberoptic bronchoscopy with various biopsy techniques is the recommended procedure of choice. In bronchoalveolar lavage (BAL) fluid, a lymphocytosis is quite sensitive but less specific, whereas an increased CD4:CD8 ratio increase is less sensitive but highly specific for sarcoidosis. Additional tests include pulmonary function testing, laboratory tests, and screening for important extrathoracic organ involvement. The best way to assess the activity is still through traditional clinical investigations on the basis of onset, worsening, or persistence of symptoms or signs directly related to sarcoidosis.[1,3]

After the diagnosis has been confirmed the diagnostic procedures should accomplish the following goals: evaluate the extent and severity of organ involvement; assess whether the disease is stable or likely to progress; determine if the patient will benefit from treatment. The role of BAL in this regard will be discussed.

IMMUNOLOGY

Sarcoidosis is a disease in which the understanding of the inflammatory response of the lung was changed markedly by BAL. More than 30 years ago, the immune response of sarcoidosis was described as a suppressed reaction.[4] This interpretation was based on the observation that patients with sarcoidosis were unusually anergic, often converting a previous positive reaction to tuberculin to a negative one. In addition, many sarcoidosis patients had a reduction of the number of circulating peripheral lymphocytes.[5] This lymphopenia was the presumed cause of the anergy. It also meant that the patient had a suppressed immune response. One feature suggesting immune upregulation was the hypergammaglobulinemia seen in some patients. All this changed with the series of studies of BAL in sarcoidosis.[4,6,7]

Formation of Granuloma in Sarcoidosis

The sarcoid granuloma is considered to be the consequence of a crippled immunological response against an unidentified antigen. It is thought that the antigen(s) that trigger the development of granulomatous lesions favor the progressive accumulation and activation of T helper (Th) 1 clones (see also Fig. 1[8]). The granulomatous lung inflammation involved in sarcoidosis is preceded by a mononuclear cell alveolitis.[5,8,9] The accumulation of these phagocytes leads to the formation of discrete structures, composed of a central core of epithelioid cells and a surrounding rim of activated alveolar macrophages and T lymphocytes releasing several cytokines.[10,11] The produced proinflammatory cytokines include interleukin (IL)-1, IL-12, IL-18, and tumor necrosis factor (TNF)-α. This immunology reaction is reflected in the alveolitis depicted by BAL fluid analysis.

The infiltrate of CD4 + activated T cells represents the immunological hallmark of sarcoidosis.[1,3,5,8] CD4 + Th lymphocytes usually regulate immune responses in the lungs as effector T lymphocytes (helper or inducer). Heterogeneity of Th lymphocytes is necessary for the development of granulomas and is classified into two functional types, Th1 and Th2. T cell dichotomy has been reported in several human immunological responses. Cytokines, predominantly of the Th1 type, participate in cell-mediated immune responses such as delayed-type hypersensitivity reactions. In contrast, cytokines of the Th2 type are products that are important for development of B cells and eosinophilia.[5] Moreover, Th1 lymphocytes are thought to control Th2 lymphocyte responses and vice versa. Cytokines produced by Th1 lymphocytes block the proliferation and differentiation of mast cells or eosinophils induced by cytokines produced by Th2 cells. Thus the functional balance between predominantly Th1 or Th2 cytokines, the Th1:Th2 ratio, and other cytokines is an important determinant in many responses.[5,8,10]

The Th1:Th2 Paradigm

It has been suggested that many immune responses in chronic diseases start predominantly as functional Th1 response characterized by the cytokines interferon-γ, IL-2, IL-12, and IL-18, and then shift to a more Th2 response.[5,8,10] The progression of a granulomatous response in sarcoidosis toward irreversible fibrosis might be explained by a change of the alveolitis phenotypically to a more balanced, mixed distribution of Th1 and Th2 subtypes ("Th0 pattern"), or rather more likely, the Th1:Th2 balance shifts toward a Th2 response. Th2 cytokines include IL-4 and IL-10. The idea is that alterations of the Th1:Th2 balance play an important role in determining the organization of the sarcoid granuloma and the evolution of the disease. A more pronounced functional Th1 balance may be a useful prognostic indicator in the clinical evaluation of patients with sarcoidosis.[8,12]

The CD4:CD8 Ratio

Bronchoalveolar lavage is able to recover cells and solutes. Lymphocytes have been shown to be predominantly activated T cells of the Th1 phenotype accumulating in all involved organs. Phenotypically, these cells are characterized by expression of CD4, human leukocyte antigen (HLA)-DR and other activation markers.[1,3,5,8,13] The increased CD4:CD8 ratio at sites of involvement has been included in the definition of sarcoidosis in 1991, whereas the more recent update of the definition in

Downloaded by: RWTH Aachen. Copyrighted material.

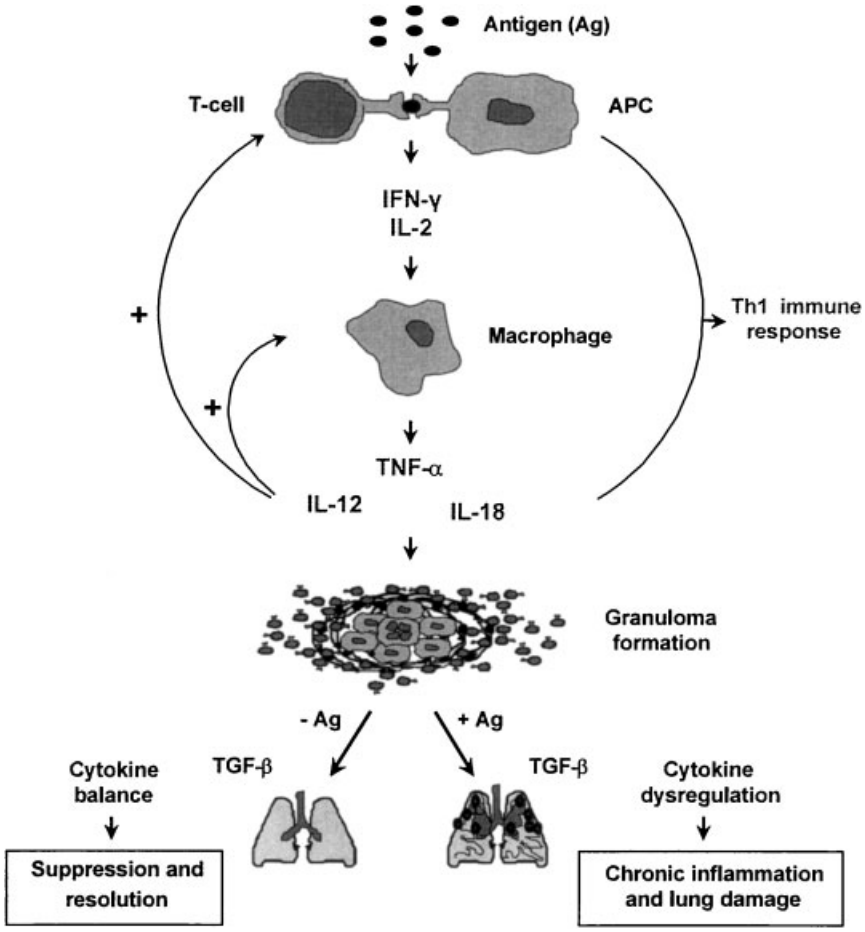

Figure 1 Hypothetical model of the pathogenesis of sarcoidosis. An inciting agent induces antigen-specific, Th1-mediated granulomatous inflammation with production of Th1 cytokines such as interferon (IFN)-γ and interleukin (IL)-2. Macrophages, activated directly by the inciting agent and by IFN-γ, produce IL-12, tumor necrosis factor (TNF)-α, IL-6, and other cytokines important in cell activation, proliferation, and recruitment. Activated macrophages and T-cells along with other effector cells, such as fibroblasts, orchestrate the complex process of granuloma formation under the regulatory influence of local cytokine production. Removal of the inciting agent allows immunosuppressive cytokines such as tumor growth factor (TGF)-β to downregulate the immune response with return to cytokine homeostasis. Granuloma regression likely occurs by cell apoptosis. Persistent antigenic stimulation results in cytokine dysregulation and, possibly, T cell autoimmune responses. If untreated, chronic antigenic stimulation and cytokine production results in tissue injury, which, together with upregulated production of TGF-β and other profibrotic cytokines, leads to irreversible fibrosis. Adapted from Moller.[8]

the American Thoracic Society/European Respiratory Society (ATS/ERS) Statement of 1999 replaced the CD4:CD8 ratio with "heightened Th1 immune response."[2] The reduction in lymphocyte numbers that is frequently observed in peripheral blood of patients with sarcoidosis has been attributed to the localized T cell accumulation in tissues affected by granulomatous inflammation.[5,8]

BRONCHOALVEOLAR LAVAGE FEATURES IN SARCOIDOSIS

BAL has added immensely to our understanding of the immunopathogenesis of sarcoidosis, and several studies have shown a good correlation between the type and number of inflammatory cells obtained by BAL and those observed in histological sections of lung biopsy specimens.

Lymphocytes

Granulomatous lung inflammatory disorders such as sarcoidosis, extrinsic allergic alveolitis, associated with inhalation of antigens causing a host response or drug-induced pneumonitis may display similarities in clinical presentation. However, these latter disorders demonstrate a different cellular profile in BAL fluid.[7,14,15] Clinical manifestations of sarcoidosis depend on the intensity of the inflammation and organ systems affected. In BAL fluid an increased number of lymphocytes, predominantly activated Th cells, can be found in 90% of sarcoidosis patients at the time of diagnosis.[16]

Downloaded by: RWTH Aachen. Copyrighted material.

In a fresh wet mount BAL fluid cell preparation from a patient with active sarcoidosis and viewed under phase contrast microscopy, the appearance of lymphocytes stuck to the surface of alveolar macrophages (AMs)—rosettes—is striking.[15] The cells adhere and do not fall off and are not phagocytosed by the AMs.

Alveolar Macrophages

In addition to lymphocytes, AMs are activated in sarcoidosis,[17] mainly by interferon-γ secreting Th1 cells. This cytokine is the key in the Th1 response seen in sarcoidosis and other granulomatous disorders.[5,8] Features of enhanced macrophage activity are the high levels of oxygen-free radicals released by AMs.[18,19] Moreover, AMs release higher levels of IL-1, IL-12, IL-18, and TNF.[5,8,20] Unfortunately, the products of AMs and other airway cells have not proved to be a useful guide for detecting sarcoidosis or monitoring therapy. However, they have provided a better understanding of the immunologic response in sarcoidosis.[5,8]

Cell Profile

When interpreting the cell differentials in regard to the differentiation of sarcoidosis versus other interstitial lung diseases (ILDs), no single parameter is important, but a combination of several features: a normal or only mildly elevated total cell count with a predominance of lymphocytes, a usually normal percentage of eosinophils and neutrophils, and the lack of plasma cells and "foamy" alveolar macrophages is characteristic for sarcoidosis.[21] Winterbauer et al found that sarcoidosis patients had higher CD4:CD8 ratios, fewer neutrophils, and 1% or less eosinophils in the BAL cell populations.[22] In late or advanced sarcoidosis, neutrophils may also be increased, as well as the number of mast cells.[23,24] Therefore, a computer program for BAL data was established. This program allows differentiating between three major ILDs using a discriminate analysis of logistic regression, with excellent accuracy.[21,25] Table 1 illustrates which parameters are needed to provide the most likely diagnosis using data obtained from BAL fluid analysis. To date, the CD4:CD8 ratio is of less importance in an individual case.

CD4:CD8 Ratio in Bronchoalveolar Lavage Fluid

Diseases with an increased number of lymphocytes in BAL fluid can be further differentiated into those with an elevated, normal, or decreased CD4:CD8 ratio. However, neither the number of lymphocytes nor the CD4:CD8 ratio in BAL fluid is a specific feature of any lung disease.[26] The CD4:CD8 ratio is increased in ~50 to 60% of patients with sarcoidosis. The diagnostic value of this ratio has been debated recently because of the high variability in sarcoidosis.[6,27] The ratio may even be decreased in 15% of patients.[14] Nevertheless, various independent groups found almost identical values for the sensitivity and specificity of an elevated BAL CD4:CD8 ratio for diagnosing sarcoidosis.[22,28] A ratio of above 3.5 has a sensitivity of 52 to 59% and a specificity of 94 to 96%. Several studies reached similar conclusions: in patients with a clinical/radiological picture typical of sarcoidosis; an elevated CD4:CD8 ratio in BAL may confirm the diagnosis and obviate the need for confirmation by additional biopsy. In the study of Winterbauer et al[22] transbronchial lung biopsy had a specificity of 89% for the distinction between sarcoidosis and other forms of diffuse lung disease and was therefore no better than

Table 1 Characteristics of a Patient with Diffuse Interstitial Damage

Personal Characteristics		*Most Likely Diagnosis Predicted by the Computer Program*
Name patient	Key	Probability of bacterial infection = 0%
Age (15–80 years)	45	
Sex	○ male ⊙ female	
Smoking	○ yes ⊙ no	
Date of birth	12–12–1959	
Patient ID number	18181818	As a bacterial infection is unlikely, the outcomes are:
BAL Fluid Analysis Results		
Fluid in (30–300 mL)	200	1 = sarcoidosis = 99.2%*
Fluid out (0–300 mL)	120	
Cell count × 10^4 /mL	16.1	2 = hypersensitivity pneumonitis or extrinsic allergic alveolitis
Eosinophils (%)	0.5	or drug-induced pneumonitis = 0.3%
Neutrophils (%)	1.0	3 = idiopathic pulmonary fibrosis = 0.4%
Lymphocytes (%)	30.0	
Macrophages (%)	69.5	

*The bronchoalveolar lavage (BAL) fluid analysis results have to be interpreted with care, and clinical data are mandatory to make the final decision about the most probable diagnosis. Note that this program is limited to the differentiation between the three major interstitial lung diseases (ILDs) only. Other ILDs have not been tested. The only intention of this program is to support other important clinical diagnostic procedures. Notably, the CD4:CD8 ratio of in the BAL fluid of this patient appeared to be 1.2. Despite this low ratio the most likely diagnosis is sarcoidosis.

Downloaded by: RWTH Aachen. Copyrighted material.

the CD4:CD8 ratio for this distinction. A recent study aimed to quantify how the likelihood for a given diagnosis changes with the knowledge of BAL cell differentials and the CD4:CD8 ratio. Welker et al[28] found that, when lymphocytes were combined with the CD4:CD8, the probability of sarcoidosis was doubled if the CD4:CD8 ratio was high. They were able to demonstrate an added informative value of the CD4:CD8 ratio, especially in sarcoidosis and hypersensitivity pneumonitis.[28]

Application of Iron Staining

Wegener's granulomatosis may demonstrate a (subclinical) lymphocyte alveolitis similar to sarcoidosis.[29] Wegener's granulomatosis and other vasculitides, idiopathic pulmonary hemosiderosis, collagen vascular diseases, and drug reactions can be associated with diffuse alveolar hemorrhage (DAH) or the alveolar hemorrhage syndromes. This can be established by BAL, even if the bleeding is occult, by identifying numerous hemosiderin-laden macrophages.[29,30] Therefore, the application of iron staining might be helpful to distinguish Wegener's granulomatosis (especially those cases with a low activity) from sarcoidosis because both disorders may have predominantly lymphocytes in BAL fluid.[31]

Cytokines and Chemokines

The number of cytokines and other biological mediators detected and quantified in the lower respiratory tract continues to increase,[20] but none has yet achieved clinical relevance. Cytokines released by AMs are important in the process of granuloma formation and regulation of the Th1:Th2 balance. Th1-related cytokines include interferon-γ and IL-2.[5,8] TNF-α is one of the most important cytokines in the disease process of sarcoidosis, and anti-TNF treatment appeared successful in refractory sarcoidosis.[32] Ziegenhagen et al[9] demonstrated that chronic sarcoidosis patients with progressive disease, especially those with a corticosteroid-resistant disease, are characterized by significantly increased TNF-α release of cultured AMs.

Identifying Special Cells

Although bilateral mediastinal or hilar lymphadenopathy is most frequently caused by the benign and often self-limiting disease sarcoidosis, disorders that require rapid diagnosis and appropriate treatment such as malignant lymphomas should be excluded.[33] To detect and further classify malignant lymphomas, histological evaluation is required. However, obtaining representative tissue samples may be a major problem. Pulmonary localization of Hodgkin disease has been confirmed by identification of Reed-Sternberg cells in a BAL fluid specimen.[34–36] Reed-Sternberg cells and their mononucleated variants can be recognized by their characteristic cytomorphological features, although care must be taken not to misinterpret reactive binucleated macrophages as neoplastic cells. In patients with Hodgkin disease, Reed-Sternberg cells should be sought when an alveolar lymphocytosis is present. Wisecarver et al[37] performed BAL in 24 patients suffering from Hodgkin disease with abnormal chest roentgenograms. In four (17%), there were Reed-Sternberg cells or their mononucleated variants in the lavage fluid and an alveolar lymphocytosis averaging 31.4% (normal: 11.5%). The lymphocytes were small and monotonous. They suggested that pulmonary Hodgkin disease can be diagnosed by BAL in some cases. Immunocytochemistry using either or both monoclonal and polyclonal antibodies was of value in the identification and classification of cells in non-Hodgkin lymphoma.[36] Furthermore, it was demonstrated that patients with malignant lymphomas had the lower CD4:CD8 ratio in BAL fluid, as well as in peripheral blood, compared with sarcoidosis patients.[38] Moreover, occasionally, plasma cells were present in BAL fluid samples.[39] Plasma cells are seldom found in BAL fluid. If present the most likely diagnosis is EAA or drug-induced pneumonitis. However, these cells are normally not present in BAL fluid obtained from sarcoidosis patients.[39] The absence of a dominant B cell clone detection in BAL fluid could help to dismiss invasive investigations of pulmonary lesions. The detection of a dominant B cell clone would lead to the performance of a pulmonary biopsy to get histological diagnosis in primary pulmonary lymphoma and, by contrast, would avoid the need for biopsy in the setting of a secondary pulmonary lymphoma.[34] Identification of paraproteins in BAL fluid may be of additional value to distinguish between a pulmonary localization of a malignant lymphoma and other pulmonary disorders with similar clinical presentation.[40]

Identifying Foreign Bodies in Bronchoalveolar Lavage Fluid

Although the cause or causes of sarcoidosis remain unknown, increasing numbers of studies support a putative role for biological agents.[41] In some cases it is really a misdiagnosed case of environmental antigen–induced disorder (see also Fig. 2[42]). Moreover, occupational and environmental exposures can cause reactions similar to sarcoidosis. One well-known misdiagnosis is chronic beryllium disease (CBD).[43,44] Some CBD cases first carried the diagnosis of sarcoidosis, given the strong similarities between the two conditions.[45] A beryllium lymphocyte proliferation

Downloaded by: RWTH Aachen. Copyrighted material.

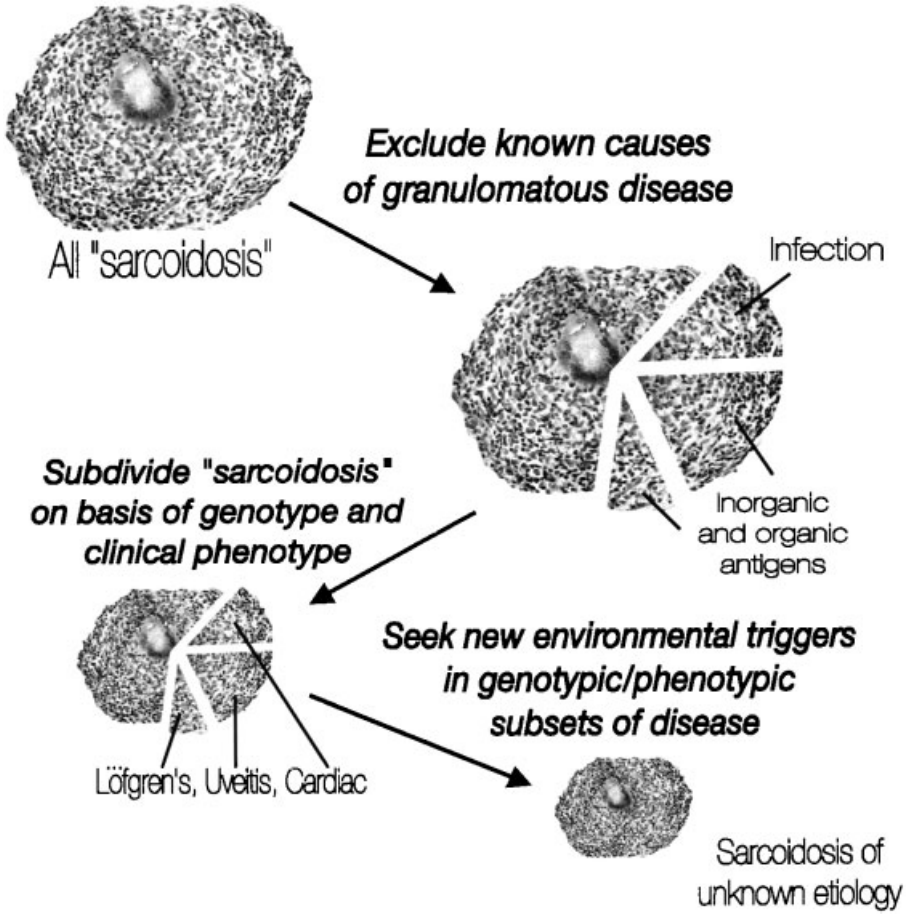

Figure 2 Proposed schema for possible etiologies of sarcoidosis. To address the cause or causes of sarcoidosis, first consideration should be given to distinguishing between granulomatous disorders of known etiology from those that are idiopathic. At present, some cases of so-called sarcoidosis are due to known environmental agents. Using available clinical and research tools, it is important to thoroughly exclude known infectious agents (such as mycobacteria), organic antigens (such as thermophiles and fungi that produce granulomatous pneumonitis), and inorganic antigens (such as beryllium and other metals). If sarcoidosis has more than one cause because the disorder itself is a heterogeneous collection of disorders, the next step will be to refine the phenotypes. It is possible to capitalize on what is now known both clinically and genetically to separate subsets of ''sarcoidosis.'' For example, there is now ample evidence to suggest that Löfgren syndrome is a separate disease, based on its genetics, immunology, clinical phenotype, and behavior. The same might be said for sarcoidosis that predominantly presents with uveitis, as seen in Japan, and possibly cardiac sarcoidosis. By purifying the clinical phenotype and genotype, thus reducing sarcoidosis heterogeneity, it will be easier to then examine the possible environmental causes of each of those separate conditions, be they microbial or not. (Source: Newman,[42] with permission.)

test in either blood or BAL fluid can be very helpful in suspected cases, but even in cases where an exposure was not recalled by the patient. Moreover, man-made mineral fibers[46,47] and metals[48–50] are considered triggers initiating a granulomatous response similar to sarcoidosis. Such cases would meet current definitional criteria for sarcoidosis, including etiology unknown, until investigators were able to identify an etiologic agent or a common point source of exposure.[42] Evaluation must include careful consideration of the home and workplace and biological monitoring, including careful search for foreign bodies, the presence of birefringent material, or inclusion bodies in AMs in BAL fluid samples.

THE BRONCHOALVEOLAR LAVAGE FLUID PROFILE VARIES WITH THE CLINICAL PRESENTATION OF SARCOIDOSIS

In sarcoidosis, BAL fluid shows a lymphocytic alveolitis in 90% of patients at the time of diagnosis. The total cell count in BAL is usually only mildly elevated in sarcoidosis, in contrast to the marked elevation in hypersensitivity pneumonitis or EAA.[14] The relative proportion of lymphocytes is somewhat higher in clinically active disease (range 20 to 80, mean around 40%), but clinically inactive sarcoidosis patients have a lower percentage (mean of 30%). There is considerable overlap in lymphocytes between active and inactive disease, and BAL may be normal in 10 to 15% of patients.[7,51] Neither

Downloaded by: RWTH Aachen. Copyrighted material.

the percentages of lymphocytes, T lymphocytes, or B lymphocytes discriminated sarcoidosis from nonsarcoidosis patients.

The clinical findings related to the involvement of specific organs vary in frequency. There are two different types of onset in sarcoidosis patients. Acute sarcoidosis has an abrupt onset and may present as Löfgren syndrome, which is characterized by bilateral hilar adenopathy, ankle arthritis, and erythema nodosum and frequently constitutional symptoms.[13,52] Generally, chronic sarcoidosis has an insidious onset, and organ-related symptoms are often related to the pulmonary infiltration. In a study evaluating BAL fluid samples obtained from sarcoidosis patients ($n = 100$) the most characteristic features of alveolitis in sarcoidosis (lymphocytosis and high CD4:CD8 ratio) were established in patients with Löfgren syndrome ($n = 22$), suggesting a systemic instead of a local immune response.[51] Moreover, the alveolitis was less pronounced in smokers.[51] Recently, it was shown that even within patients with Löfgren syndrome, differences in outcome and BAL fluid profile appeared. It is known that DRB1*0301/DQB1*201-positive patients with sarcoidosis demonstrate a more pronounced inflammatory profile and more favorable outcome.[13] Therefore, the clinical presentation of sarcoidosis and the smoking status of a sarcoidosis patient and, in the near future, genomics, are crucial for interpreting individual lavage analysis results.

ASSESSMENT OF ACTIVITY AND PROGNOSIS IN BRONCHOALVEOLAR LAVAGE FLUID

The term *activity* is frequently used in sarcoidosis but is often misinterpreted. Activity should not be confused with the extent or severity of the disease (i.e., the number of involved organs, or the density of granulomas within an involved organ), must also not be associated with unfavorable prognosis (e.g., the highly active acute disease, manifesting as Löfgren syndrome, has the best prognosis), and also not be misjudged with the necessity of initiating corticosteroid therapy.[2,8]

A long list of laboratory and cell biological markers has been discussed regarding potential indices of active disease, either in serum or in BAL fluid.[5,8,53] However, none of them can be recommended for routine assessment. Active disease means that the disease has not yet come to a rest, that there is still ongoing T cell and macrophage inflammation and granuloma formation, reflected by increased serum soluble IL-2-receptor levels or angiotensin-converting enzyme (ACE) levels, with the potential that the disease may progress, whereas inactive disease means that the disease has come to a rest and will likely not progress. At present, the best way to assess the activity of sarcoidosis is still through traditional clinical investigations.[3,53] The clinical activity is assessed on the basis of onset, worsening, or persistence of symptoms or signs directly related to sarcoidosis. These may be constitutional symptoms, the new development or changes of skin lesions, in combination with changes in chest radiography, and in lung function test results. Moreover, it is of more clinical relevance to depict disease extent and severity rather than the activity of sarcoidosis in an individual patient.

The quantification and also the subtyping of lymphocytes in BAL fluid have not fulfilled the early promise of being useful markers of disease activity. Initial reports have suggested that patients with a high intensity alveolitis showed clinical deterioration, and patients with a low intensity alveolitis remained stable.[3,51,52] However, the prognostic value of BAL lymphocytes and its value as an indicator for corticosteroid therapy were subsequently shown to be questionable. Many subsequent studies have shown that the degree of lymphocytosis at time of diagnosis is of no prognostic significance.[3,28,51,52] Additionally, patients with a good prognosis and high likelihood of spontaneous remission, such as those with acute sarcoidosis (Löfgren syndrome), can have very high CD4:CD8 ratios.[13,51] In line with this, Planck et al[12] demonstrated that an increased BAL fluid CD4:CD8 ratio was associated with a favorable prognosis as demonstrated in patients suffering from Löfgren syndrome.[13,51,52]

The prognostic value of increased neutrophils seems to be more promising. Two independent groups have shown that increased neutrophils ($> 3.0\%$) in BAL fluid obtained from newly diagnosed pulmonary sarcoidosis correlated with clinical deterioration during follow-up and a significantly higher risk of necessity for steroid therapy.[9,24] Furthermore, of the serological parameters investigated, only serum levels of soluble IL-2 receptor and neopterin were associated with disease severity.[9]

EXTRATHORACIC MANIFESTATIONS AND BRONCHOALVEOLAR LAVAGE FLUID FEATURES

In patients with extrapulmonary sarcoidosis, a gradual progression of the T cell alveolitis may occur. In a substantial percentage of patients with extrapulmonary sarcoidosis there is a discrepancy between chest radiographic abnormalities and the presence of an alveolitis as determined by immunologic marker analysis. In some cases, the alveolitis remains subclinical, whereas others present with pulmonary symptoms.[1,3] This alveolitis reflects a local expression of a disseminated immunologic reaction. Also, in cases of extrathoracic manifestations such as ocular sarcoidosis and erythema nodosum, features of an alveolitis suspected of sarcoidosis can be found.[54] For example, in the case of uveitis with unknown cause, BAL fluid analysis may be

Downloaded by: RWTH Aachen. Copyrighted material.

sufficient to allow a diagnosis of sarcoidosis without biopsy confirmation.

As mentioned earlier, a BAL lymphocytosis is nonspecific and seen in many other disorders as well as in extrathoracic granulomatous diseases, such as Crohn disease and primary biliary cirrhosis.[55] These latter disorders may demonstrate a (subclinical) lymphocytic alveolitis similar to sarcoidosis.[55]

INFECTIOUS DISORDERS MIMICKING SARCOIDLIKE GRANULOMAS

Nonproductive cough, dyspnea, and chest pain are common features of pulmonary sarcoidosis. These features are nonspecific and can also be seen in a lot of infectious diseases. *Legionella pneumophila*, *Chlamydia pneumoniae*, *Mycoplasma pneumoniae*, *Bordetella* (*para*) *pertussis*, as well as *Mycobacterium tuberculosis* may present rather atypically and therefore initially be hard to distinguish from sarcoidosis. Many granulomatous infections may mimic a sarcoidlike granulomatous reaction and should be considered in the differential diagnosis.[1,3,56]*Borrelia burgdorferi* causing Lyme disease, *Rickettsia* causing Q-fever, the protozoan *Leishmania* spp., and *Mycobacterium tuberculosis* among others may present similarly to sarcoidosis. In such cases BAL fluid analysis may also reveal a lymphocytosis indistinguishable from alveolitis seen in sarcoidosis. Even with well advanced pathological and microbiological examination, it could be hard to make the appropriate diagnosis. Moreover, sarcoidosis patients receiving corticosteroids or other immunoregulatory drugs are susceptible to opportunistic infections.[57–61] Clinical deterioration in those cases may justify BAL fluid analysis with advanced microbial diagnostic procedures including various polymerase chain reactions (PCRs) and the *Aspergillus* antigen test (galactomannan; see also article on infectious disorders).

Case Report

A 33-year-old man was referred to the Sarcoidosis Management Center of University Hospital of Maastricht for a second opinion because of refractory sarcoidosis. BAL fluid analysis showed a lymphocytosis compatible with sarcoidosis; culture was negative. Moreover, a biopsy of the bronchus demonstrated a granulomatous reaction consistent with sarcoidosis. Despite the initiated treatment with steroids his complaints of coughing and dyspnea did not improve. Echocardiography revealed dilatation of the right ventricle, with tricuspidal insufficiency 2/4 and pulmonary valve insufficiency. The vena cava did not collapse. These signs are indicative of an elevated pulmonary artery pressure. Abdominal CT showed lymphadenopathy, especially between the kidney and aortic bifurcation. Additionally, a small bowel biopsy was performed showing an accumulation of foamy macrophages in the lamina propria. Staining with PAS (para aminosalicilic acid) showed the purple positive granules (lysosomes with partially digested bacilli) in the foamy macrophages. Accordingly, it was concluded that this patient was suffering from Whipple disease. Possible explanation of the pulmonary hypertension could be vascular infiltration by *Tropheryma whippelii*.[62] According to other reports,[62,63] in this case the pulmonary hypertension (normalizing of the echocardiography) resolved after treatment with antibiotics (ceftriaxone during 2 weeks and cotrimoxazole for a period of 1 year) and his clinical situation dramatically improved.

Even with pathological and microbiological examination it could be hard to distinguish sarcoidosis from Whipple disease. Pulmonary involvement is frequent. A pitfall in making the right diagnosis is that PAS staining of extraintestinal inflamed tissue can be negative in patients with Whipple disease.[62] Whipple disease is a systemic infectious disorder affecting mostly middle-aged white males. It is of great importance to establish the right diagnosis because appropriate antibiotic therapy is mandatory.[62,63]

CONCLUSION

In conclusion, sarcoidosis is a multisystem disease of unknown etiology, histopathologically defined by the presence of epithelioid cell granulomata in multiple organs. Bronchoalveolar lavage (BAL) has been used as a research tool for many years and offered insight into the immunologic process involved in sarcoidosis. Clinically, BAL is useful in the diagnostic workup, even in cases of extrapulmonary involvement only. However, in clinical practice it has limited value in the follow-up of patients with sarcoidosis and should not be routinely applied to patients with sarcoidosis in this regard. However, in cases of clinical deterioration BAL fluid analysis with advanced microbial diagnostic procedures is justified to exclude (opportunistic) infections.

REFERENCES

1. Baughman RP, Lower EE, du Bois RM. Sarcoidosis. Lancet 2003;361:1111–1118
2. Hunninghake GW, Costabel U, Ando M, et al. ATS/ERS/WASOG statement on sarcoidosis. American Thoracic Society/European Respiratory Society/World Association of Sarcoidosis and other Granulomatous Disorders. Sarcoidosis Vasc Diffuse Lung Dis 1999;16:149–173
3. Costabel U. Sarcoidosis: clinical update. Eur Respir J Suppl 2001;32:56s–68s
4. Hunninghake GW, Crystal RG. Pulmonary sarcoidosis: a disorder mediated by excess helper T-lymphocyte activity at sites of disease activity. N Engl J Med 1981;305:429–434

Downloaded by: RWTH Aachen. Copyrighted material.

5. Semenzato G, Bortoli E, Brunetta C, et al. Immunology and pathophysiology. Eur Respir Mon 2005;32:49–64
6. Baughman RP, Drent M. Role of bronchoalveolar lavage in interstitial lung disease. Clin Chest Med 2001;22:331–341
7. Costabel U, Guzman J. Bronchoalveolar lavage in interstitial lung disease. Curr Opin Pulm Med 2001;7:255–261
8. Moller DR. Treatment of sarcoidosis—from a basic science point of view. J Intern Med 2003;253:31–40
9. Ziegenhagen MW, Rothe ME, Zissel G, et al. Exaggerated TNFalpha release of alveolar macrophages in corticosteroid resistant sarcoidosis. Sarcoidosis Vasc Diffuse Lung Dis 2002; 19:185–190
10. Wahlstrom J, Katchar K, Wigzell H, et al. Analysis of intracellular cytokines in CD4+and CD8+lung and blood T cells in sarcoidosis. Am J Respir Crit Care Med 2001;163: 115–121
11. Baughman RP, Strohofer SA, Buchsbaum J, et al. Release of tumor necrosis factor by alveolar macrophages of patients with sarcoidosis. J Lab Clin Med 1990;115:36–42
12. Planck A, Eklund A, Grunewald J. Inflammatory BAL-fluid and serum parameters in HLA DR17 positive vs. DR17 negative patients with pulmonary sarcoidosis. Sarcoidosis Vasc Diffuse Lung Dis 2001;18:64–69
13. Grunewald J, Eklund A, Olerup O. Human leukocyte antigen class I alleles and the disease course in sarcoidosis patients. Am J Respir Crit Care Med 2004;169:696–702
14. Drent M, Grutters JC, Mulder PG, et al. Is the different T helper cell activity in sarcoidosis and extrinsic allergic alveolitis also reflected by the cellular bronchoalveolar lavage fluid profile? Sarcoidosis Vasc Diffuse Lung Dis 1997;14:31–38
15. Reynolds HY. Use of bronchoalveolar lavage in humans: past necessity and future imperative. Lung 2000;178:271–293
16. Yeager H Jr, Williams MC, Beekman JF, et al. Sarcoidosis: analysis of cells obtained by bronchial lavage. Am Rev Respir Dis 1977;116:951–954
17. Thomas PD, Hunninghake GW. Current concepts of the pathogenesis of sarcoidosis. Am Rev Respir Dis 1987;135: 747–760
18. Rottoli P, Magi B, Cianti R, et al. Carbonylated proteins in bronchoalveolar lavage of patients with sarcoidosis, pulmonary fibrosis associated with systemic sclerosis and idiopathic pulmonary fibrosis. Proteomics 2005;5:2612–2618
19. Psathakis K, Papatheodorou G, Plataki M, et al. 8-Isoprostane, a marker of oxidative stress, is increased in the expired breath condensate of patients with pulmonary sarcoidosis. Chest 2004;125:1005–1011
20. Rottoli P, Magi B, Perari MG, et al. Cytokine profile and proteome analysis in bronchoalveolar lavage of patients with sarcoidosis, pulmonary fibrosis associated with systemic sclerosis and idiopathic pulmonary fibrosis. Proteomics 2005; 5:1423–1430
21. Drent M, Jacobs JA, Cobben NA, et al. Computer program supporting the diagnostic accuracy of cellular BALF analysis: a new release. Respir Med 2001;95:781–786
22. Winterbauer RH, Lammert J, Selland M, et al. Bronchoalveolar lavage cell populations in the diagnosis of sarcoidosis. Chest 1993;104:352–361
23. Pesci A, Bertorelli G, Gabrielli M, et al. Mast cells in fibrotic lung disorders. Chest 1993;103:989–996
24. Drent M, Jacobs JA, de Vries J, et al. Does the cellular bronchoalveolar lavage fluid profile reflect the severity of sarcoidosis? Eur Respir J 1999;13:1338–1344
25. Drent M, van Nierop MA, Gerritsen FA, et al. A computer program using BALF-analysis results as a diagnostic tool in interstitial lung diseases. Am J Respir Crit Care Med 1996; 153:736–741
26. Costabel U. CD4/CD8 ratios in bronchoalveolar lavage fluid: of value for diagnosing sarcoidosis? Eur Respir J 1997;10: 2699–2700
27. Kantrow SP, Meyer KC, Kidd P, et al. The CD4/CD8 ratio in BAL fluid is highly variable in sarcoidosis. Eur Respir J 1997;10:2716–2721
28. Welker L, Jorres RA, Costabel U, et al. Predictive value of BAL cell differentials in the diagnosis of interstitial lung diseases. Eur Respir J 2004;24:1000–1006
29. Schnabel A, Reuter M, Gloeckner K, et al. Bronchoalveolar lavage cell profiles in Wegener's granulomatosis. Respir Med 1999;93:498–506
30. Cordier JF. Pulmonary vasculitis. Eur Respir Mon 2000; 14:226–243
31. Drent M, Jacobs JA, Wagenaar SS. Bronchoalveolar lavage. In: Olivieri D, du Bois RM, eds. Interstital Lung Diseases. Eur Respir Mon 2000;14:64–78
32. Baughman RP, Drent M, Kavuru M, et al. Infliximab therapy in patients with chronic sarcoidosis and pulmonary involvement. Am J Respir Crit Care Med 2006;174:795–802
33. Carr PL, Singer DE, Goldenheim P, et al. Noninvasive testing of asymptomatic bilateral hilar adenopathy. J Gen Intern Med 1990;5:138–146
34. Zompi S, Couderc LJ, Cadranel J, et al. Clonality analysis of alveolar B lymphocytes contributes to the diagnostic strategy in clinical suspicion of pulmonary lymphoma. Blood 2004; 103:3208–3215
35. Poletti V, Romagna M, Gasponi A, et al. Bronchoalveolar lavage in the diagnosis of low-grade, MALT type, B-cell lymphoma in the lung. Monaldi Arch Chest Dis 1995; 50:191–194
36. Poletti V, Romagna M, Allen KA, et al. Bronchoalveolar lavage in the diagnosis of disseminated lung tumors. Acta Cytol 1995;39:472–477
37. Wisecarver J, Ness MJ, Rennard SI, et al. Bronchoalveolar lavage in the assessment of pulmonary Hodgkin's disease. Acta Cytol 1989;33:527–532
38. Drent M, Wagenaar SS, Mulder PH, et al. Bronchoalveolar lavage fluid profiles in sarcoidosis, tuberculosis, and non-Hodgkin's and Hodgkin's disease: an evaluation of differences. Chest 1994;105:514–519
39. Drent M, van Velzen Blad H, Diamant M, et al. Differential diagnostic value of plasma cells in bronchoalveolar lavage fluid. Chest 1993;103:1720–1724
40. Drent M, Peters FP, Jacobs JA, et al. Pulmonary infiltration associated with myelodysplasia. Ann Oncol 1997;8:905–909
41. Bagatin E, Pereira CA, Afiune JB. Granulomatous diseases of occupational etiology [in Portuguese]. J Bras Pneumol 2006;32(Suppl):S69–S84
42. Newman LS. Aetiologies of sarcoidosis. Eur Respir Mon 2005;10:23–48
43. Newman LS. Beryllium disease and sarcoidosis: clinical and laboratory links. Sarcoidosis 1995;12:7–19
44. Sawyer RT, Parsons CE, Fontenot AP, et al. Beryllium-induced tumor necrosis factor-alpha production by CD4+ T cells is mediated by HLA-DP. Am J Respir Cell Mol Biol 2004;31:122–130

Downloaded by: RWTH Aachen. Copyrighted material.

45. Muller-Quernheim J, Gaede KI, Fireman E, et al. Diagnoses of chronic beryllium disease within cohorts of sarcoidosis patients. Eur Respir J 2006;27:1190–1195
46. Drent M, Bomans PH, Van Suylen RJ, et al. Association of man-made mineral fibre exposure and sarcoidlike granulomas. Respir Med 2000;94:815–820
47. Klimczak A, Langfort R, Zych J, et al. Granulomatous lung lesions after occupational exposure to glass fibers [in Polish]. Pneumonol Alergol Pol 2000;68:273–278
48. Newman LS. Metals that cause sarcoidosis. Semin Respir Infect 1998;13:212–220
49. Werfel U, Schneider J, Rodelsperger K, et al. Sarcoid granulomatosis after zirconium exposure with multiple organ involvement. Eur Respir J 1998;12:750
50. Hull MJ, Abraham JL. Aluminum welding fume–induced pneumoconiosis. Hum Pathol 2002;33:819–825
51. Drent M, van Velzen Blad H, Diamant M, et al. Relationship between presentation of sarcoidosis and T lymphocyte profile: a study in bronchoalveolar lavage fluid. Chest 1993; 104:795–800
52. Grunewald J, Eklund A. Sex-specific manifestations of Lofgren's syndrome. Am J Respir Crit Care Med 2007;175: 40–44
53. Costabel U, Teschler H. Biochemical changes in sarcoidosis. Clin Chest Med 1997;18:827–842
54. Takahashi T, Azuma A, Abe S, et al. Significance of lymphocytosis in bronchoalveolar lavage in suspected ocular sarcoidosis. Eur Respir J 2001;18:515–521
55. Camus P, Colby TV. The lung in inflammatory bowel disease. Eur Respir J 2000;15:5–10
56. Blackmon GM, Raghu G. Pulmonary sarcoidosis: a mimic of respiratory infection. Semin Respir Infect 1995;10:176–186
57. Bongartz T, Sutton AJ, Sweeting MJ, et al. Anti-TNF antibody therapy in rheumatoid arthritis and the risk of serious infections and malignancies: systematic review and meta-analysis of rare harmful effects in randomized controlled trials. JAMA 2006;295:2275–2285
58. Baughman RP, Lynch JP. Difficult treatment issues in sarcoidosis. J Intern Med 2003;253:41–45
59. Baughman RP, Lower EE. Therapy for sarcoidosis. Eur Respir Mon 2005;32:301–315
60. Baughman RP, Lower EE. Fungal infections as a complication of therapy for sarcoidosis. QJM 2005;98: 451–456
61. Schilstra A, Rottoli P, Jacobs JA, van Suylen RJ, Galluzzi P, Drent M. Case studies to explore the pitfalls in the diagnosis of sarcoidosis. Sarcoidosis Vasc Diffuse Lung Dis 2006; 23:135–140
62. Riemer H, Hainz R, Stain C, et al. Severe pulmonary hypertension reversed by antibiotics in a patient with Whipple's disease. Thorax 1997;52:1014–1015
63. Peschard S, Brinkane A, Bergheul S, et al. Whipple disease associated with pulmonary arterial hypertension: Jarisch-Herxheimer reaction after antibiotic therapy [in French]. Presse Med 2001;30:1549–1551

Downloaded by: RWTH Aachen. Copyrighted material.